SEMAGLUTIDE DEMONSTRATES CARDIORENAL BENEFITS AND IMPROVES KIDNEY LESIONS IN THE SDT FATTY RAT, A NEW MODEL OF CARDIOVASCULAR-KIDNEY-METABOLIC SYNDROME

François Briand[1], Guillaume Bourdier[2], Estelle Grasset[1], Masami Shinohara[3], Rana Assaly[2], Caroline Dubroca[2], Thierry Sulpice[1,2]
[1]Physiogenex, Escalquens, France, [2]Cardiomedex, Escalquens, France, [3]CLEA Japan Inc., Tokyo Japan

BACKGROUND:

The high prevalence of cardiovascular-kidney-metabolic (CKM) syndrome in the population requires novel therapeutics to reduce cardiovascular death, and to this aim, predictive animal models are needed. Here we evaluated the effects of the GLP-1 receptor agonist semaglutide on kidney dysfunction and left ventricle diastolic dysfunction in the Spontaneously Diabetic Torii (SDT) fatty rat, a new type 2 diabetic animal model of CKM syndrome.

METHODS:

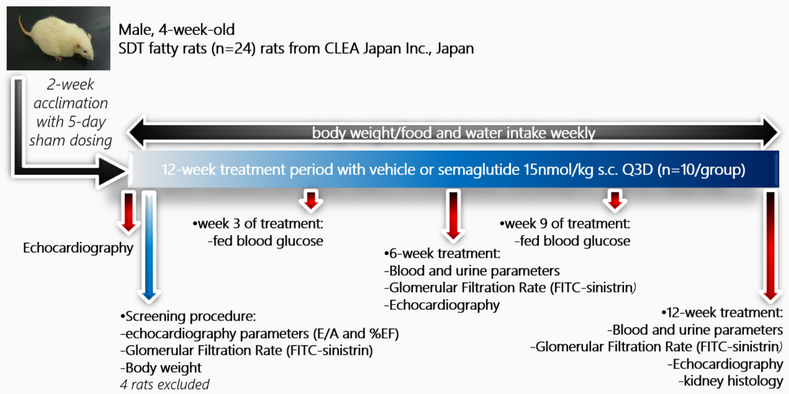

Male, 6-week-old SDT fatty rats were treated with vehicle or SEMA 15 nmol/kg s.c. Q3D for 12 weeks. At 6 weeks and 12 weeks of treatment, urine parameters and glomerular filtration rate (GFR) were measured, and cardiac function was investigated by echocardiography. Kidney histology was also performed at the end of the 12-week treatment period.

RESULTS:

1 Semaglutide reduces body weight and improves glycemic control in SDT fatty rats

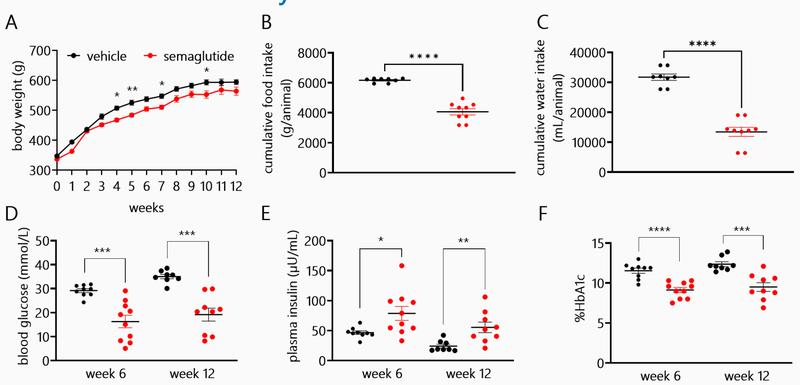

Body weight (A), cumulative food intake (B) and water intake (C), fasting blood glucose (D), plasma insulin (E) and %HbA1c (F) in SDT fatty rats treated with vehicle or semaglutide 15nmol/kg s.c. Q3D for 12 weeks.
*p<0.05, **p<0.01, ***p<0.001 and ****p<0.0001

2 Semaglutide improves kidney function and reduces kidney and heart hypertrophy in SDT fatty rats.

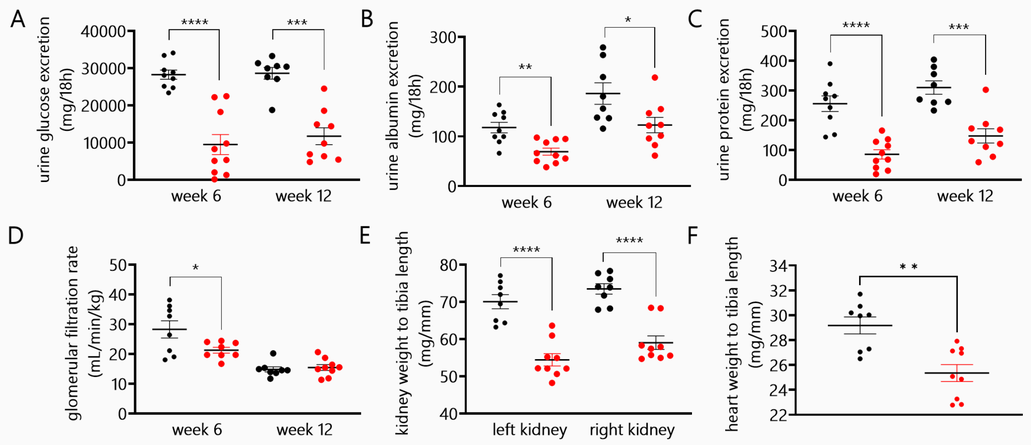

Urine glucose (A), albumin (B) and protein (C) excretion, glomerular filtration rate (D) kidney (E) and heart (F) weight in SDT fatty rats treated with vehicle or semaglutide 15nmol/kg s.c. Q3D for 12 weeks.
*p<0.05, **p<0.01, ***p<0.001 and ****p<0.0001

3 Semaglutide does not alter ejection fraction but significantly improves diastolic dysfunction in SDT fatty rats.

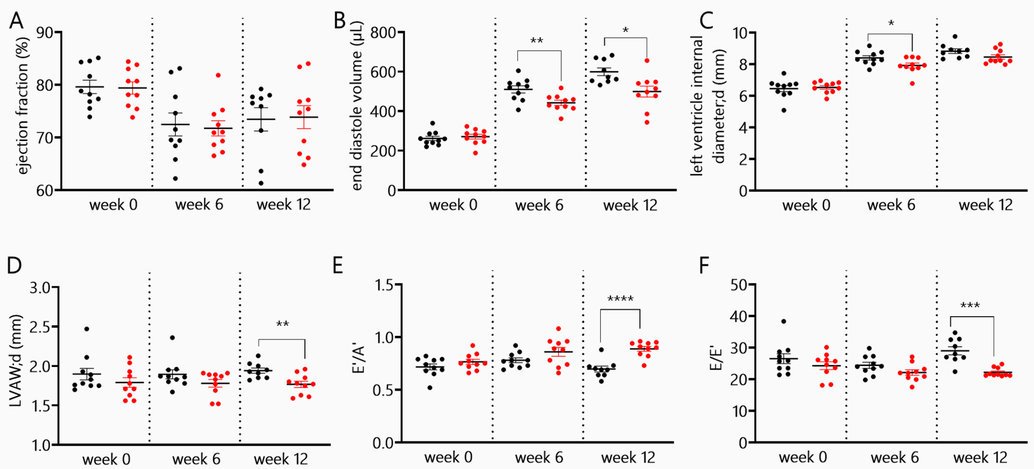

Left ventricle ejection fraction (A), end diastole volume (B) internal diameter (C) and anterial wall (D), e' to a' ratio (E) and e to e' ratio measured by echocardiography in SDT fatty rats treated with vehicle or semaglutide 15nmol/kg s.c. Q3D for 12 weeks.
*p<0.05, **p<0.01, ***p<0.001 and ****p<0.0001

3 Semaglutide improves kidney histopathological scoring in SDT fatty rats

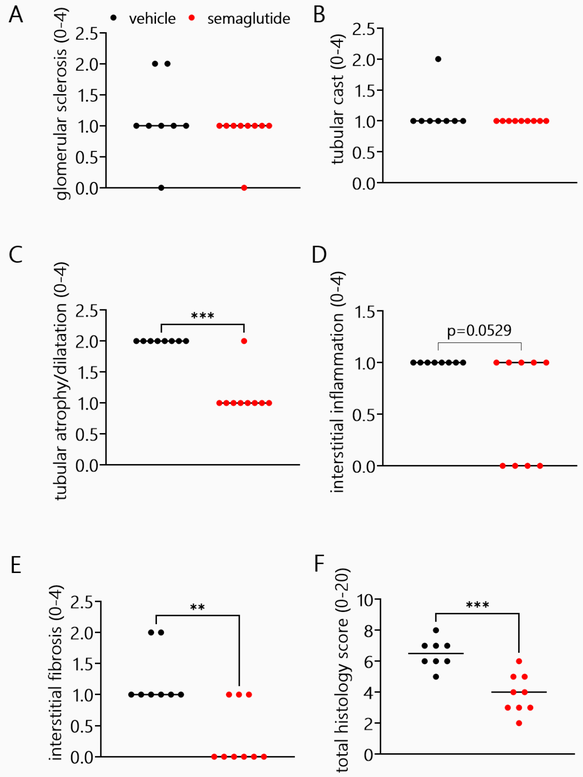

Kidney histopathological scoring for glomerular sclerosis (A), tubular cast (B) and hypertrophy/dilatation (C) interstitial inflammation (D), fibrosis (E) and total score (F) in SDT fatty rats treated with vehicle or semaglutide 15nmol/kg s.c. Q3D for 12 weeks.
*p<0.05, **p<0.01, ***p<0.001 and ****p<0.0001

CONCLUSION

- Semaglutide demonstrates cardiorenal benefits, including improved kidney lesions, in the SDT fatty rat.
- This model will be useful to evaluate novel therapies targeting CKM syndrome versus semaglutide as a standard of care.